

ABDOMINAL WALL RECONSTRUCTION WITHOUT MESH

Components Separation *Ramirez 1990*

- Undermine and make incision 1 cm lateral to linea semilunaris.
- External oblique transected laterally from its insertion into the rectus sheath and separated from internal oblique
- advance rectus and internal oblique with transversus
 - neurovascular bundle intact & bi pedicle musculofascial advancement
- Ipsilateral advance of approximately:
 - 7 - 10 cm at mid abdomen
 - 3 - 5 cm at epigastric
 - 1 - 3 cm suprapubic

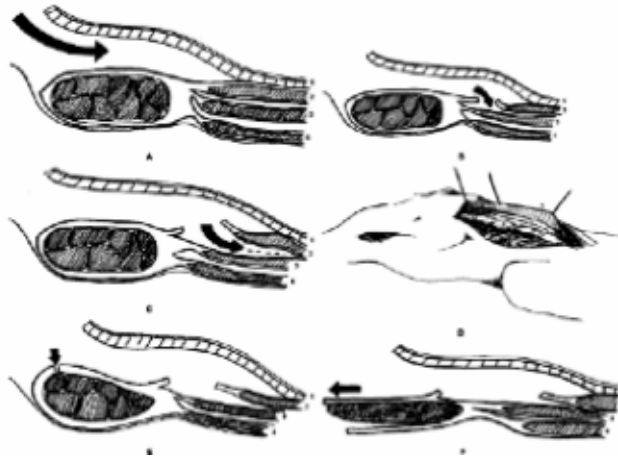


Table 1. Results of the Repair of Large Abdominal Wall Defects with the Component Separation Technique

First author	Year	Patients	Clean/ contaminated	Complications (n)	Reherniation n (%)	Followup mean (range, mo)
Ramirez ⁷	1990	11	8/3	0	0 (0.0)	? (4-42)
DiBello ⁸	1996	35 ^a	20/15	Wound infection (2) Hematoma (1) Seroma (1)	3 (8.6)	22 (1-43)
Girromo ⁹	1999	33	30/3	Wound infection (8) Enterocutaneous fistula (1)	2 (6.1)	21 (6-57)
Shestak ¹¹	2000	22	?	Wound infection (2) Seroma (1) Death (1)	1 (5)	52 (8-84)
Lowe ¹²	2000	30 ^b	?	Wound infection (12) Skin ischemia (6) Skin dehiscence (13)	3 (10)	12
Cohen ¹³	2001	24	15/9	Skin dehiscence (2) Seroma (1)	1 (4)	? (12-36)
Authors	2002	43	28/15	Wound infection (6) Hematoma (5) Seroma (2) Skin necrosis (1) Fascial dehiscence (1)	12 (30)	15.6 (12-30)

^aIn 15 patients, an onlay synthetic prosthesis was implanted as well.

^bIn 10 patients, an onlay polypropylene mesh was implanted as well.

Reilingh et al. Components Separation Technique for the Repair of Large Abdominal Wall Hernias. *J Am Coll Surg.* 2003 Jan; 196(1):32-37.

- retrospective study 1994-99 of 43 patients with component separation average defect 18 x 13 cm where mesh was contraindicated: infection, contamination, exposed bowel no omentum
- up to 20 cm at midline without release of posterior rectus sheath
- *mean f/u 15.6 months: Recurrent hernia 32.6%, 5 hematoma, 2 seroma, 6 wound infections, 1 dehiscence, 1 death from mesenteric thrombosis

Szczerba & Dumanian, Definitive Surgical Treatment on Infected or Exposed Ventral Hernia Mesh. *Ann Surg.* 2003 Mar; 237(3), 437-441.

- Retrospective study of 11 patients with ventral mesh exposed, nonincorporated, chronic drainage, or associated enterocutaneous fistula
- treated with en bloc excision of mesh and scarred fascia using modified immediate bilateral separation of parts
- emphasis was placed on preservation of perforators (skin blood flow) either through a tunneled release via the midline incision or 2 new transverse lateral incisions
- Mean F/U 24 months, average defect width 13 cm, 1 hernia recurrence, 2 stitch abscesses required removal

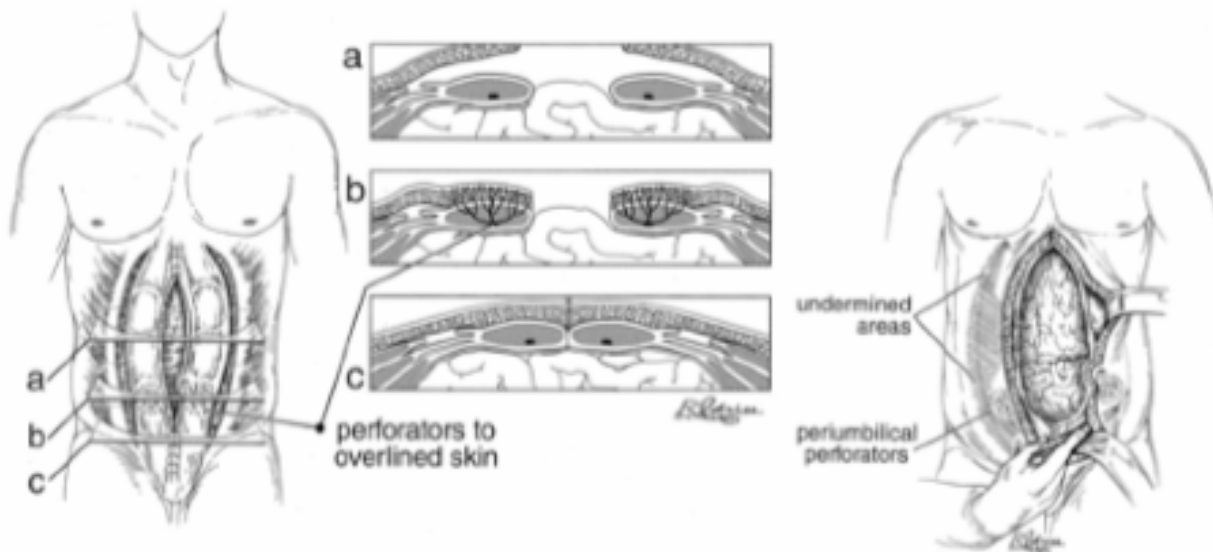


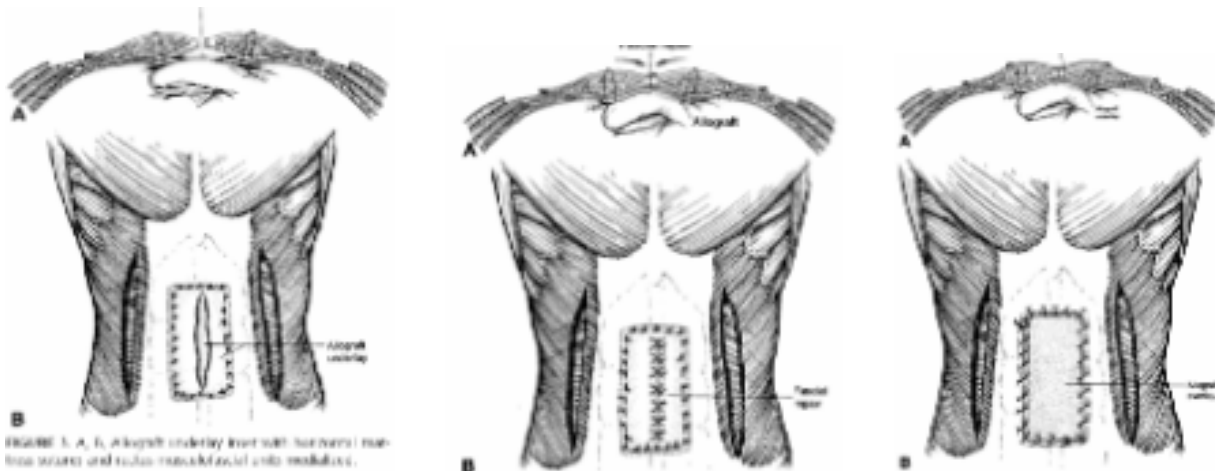
Figure 1. "Separation of parts" procedure with perforator preservation. Reprinted with permission.

Table 1. PATIENT DATA

Sex, Age	Premorbid Conditions	Prior Surgeries	Mesh Complication
M, 69	Prostate cancer	Prostatectomy, hernia	Chronic infected seroma
F, 55	NDDM, obesity, COPD	Open cholecystectomy, hernia, diverting transverse colostomy	Mesh extrusion
M, 72	Peripheral vascular disease, NDDM	Aortobifemoral bypass, incarcerated hernia	Enterocutaneous fistula through mesh
F, 52	HTN, HTN, CRI, Takayasu's, diverticulitis	Open cholecystectomy, aortic graft, TAH, Hartman's procedure, multiple hernia repairs	Mesh extrusion
F, 45	HTN, obesity	Open cholecystectomy, C-sections X3, TAH, multiple hernia repairs	Chronic infected seroma
F, 45	SLE, obesity	TAH, hernia repair	Chronic abscess
F, 76	Obesity	Exploratory laparotomy, hernia repair	Chronic abscess
M, 55	HTN, polycythemia, PE/DVT, GI bleed	Exploratory laparotomy for gastric ulcer, hernia repair	Enterocutaneous fistula through mesh
M, 31	None	Trauma laparotomy, bowel resection, hernia repair	Enterocutaneous fistula through mesh
F, 70	NDDM, colon cancer, DVT	Exploratory laparotomy for obstructing colon ca., multiple hernia repairs	Mesh extrusion
M, 30	Diverticulitis, NDDM, obesity	Colectomy for diverticular disease, multiple hernia repairs	Chronic abscess, intermittent drainage

Kolker et al. Multilayer Reconstruction of Abdominal Wall Defects With Acellular Dermal Allograft (Alloderm) and Component Separation. *Annals of Plast Surg.* 2005 Jul; 55(1): 36-42

- Retrospective: 16 patients with incisional or recurrent hernias over mean f/u 16 months
- 15 with previous prosthetic mesh (9 of which had prosthetic exposure or infection) & one with primary incisional hernia & colocutaneous fistula
- Synthetics removed, aggressive serial debridement, irrigation, wound vac
- Alloderm underlay retrofascial, fascial reapposition, Alloderm overlay
- 4-5 cm mobilization with each ipsilateral musculofascial unit
- No hernia recurrence, 2 seromas (drained 1 x), 1 wound separation with granulation tissue



Alloderm:

- acellular dermal matrix derived from cadaver
- epidermis removed with hi ionic solution uncouples bonds between layers

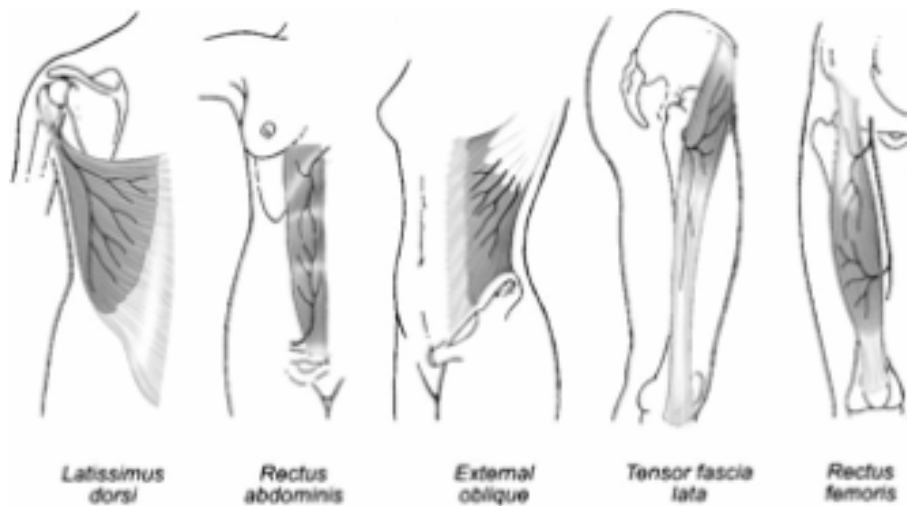
- dermal cells then removed with sodium deoxycholate, freeze dried creating human dermal collagen, elastin, and laminin within a residual dermal matrix.
- Less infection & similar breaking strength, and hernia recurrence to synthetics
- undergoes neovascularization demonstrated histologically & Wood's lamp with Fluorescein dye
- remodeled into fibrous scar tissue in animal models.

Gamba et al. Experimental abdominal wall defect repaired with acellular matrix. *Pediatr Surg Int.* 2002 Jan;(18)327-331.

Menon et al. Revascularization of Human Acellular Dermis in Full-Thickness Abdominal Wall Reconstruction in the Rabbit Model. *Ann of Plas Surg.* 2003 May: (5)50;523-527.

Muscle flaps and free flaps

- The previous methods that depend on separation of the muscle and fascial layers of the abdominal wall are not applicable when there have been multiple previous procedures involving ostomies and drain sites that distort and destroy the anatomical planes.
- Muscle flaps and free flaps are used for abdominal wall reconstruction when synthetic mesh is contraindicated and the abdominal wall is unsuitable for fascial separation and medial advancement



Local flaps

- Optimal choice for partial musculofascial defects of the lateral abdominal wall greater than 3 cm
- Rectus abdominis is flap of choice for these lateral defects.
- Can be based on a superior or inferior pedicled base
 - Superior pedicle flap: for defects of upper 2/3
 - Inferior pedicle: defects of lower 1/3 of abdomen

	Size	Pedicle Base	Pattern of Circulation	Dominant Vessels
Rectus abdominis	25 × 6 cm	Superior and inferior	Type III	Superior and inferior epigastric arteries
External oblique	20 × 40 cm	Superior	Type IV	Lateral cutaneous branches of the inferior 8 posterior intercostal arteries
Internal oblique	10 × 20 cm	Inferior	Type V	Ascending branch of the deep circumflex iliac artery

* Adapted from Mathes, S. J., and Nahai, F. *Clinical Applications of Muscle and Musculocutaneous Flaps*. St. Louis: Mosby, 1992. Pp. 364-385.

Distant flaps

- Can be used to repair midline defects larger than 10 cm, 18 cm, and 3-6 cm of the upper, middle, and lower abdomen, respectively
- Can be used to repair lateral defects larger than 5 cm, 9 cm, and 2-3 cm of the upper, middle, and lower abdomen, respectively
- The most frequently utilized muscle and musculocutaneous rotation flaps are the tensor fascia lata and rectus femoris
 - both have a vascular pedicle from the lateral femoral circumflex artery

	Flap Size	Size of Skin Island	Pattern of Circulation	Dominant Vessel
Tensor fasciae latae	5 × 15 cm	40 × 10 cm	Type I	Ascending branch of the lateral circumflex femoral artery
Rectus femoris	20 × 8 cm	12 × 20 cm	Type II	Descending branch of the lateral circumflex femoral artery
Latissimus dorsi	25 × 35 cm	30 × 40 cm	Type V	Thoracodorsal artery
Gracilis	6 × 24 cm	16 × 18 cm	Type II	Ascending branch of the medial circumflex femoral artery
Vastus lateralis	10 × 26 cm	10 × 15 cm	Type I	Descending branch of the lateral circumflex femoral artery

Adapted from Mathes, S. J., and Nahai, F. *Clinical Applications of Muscle and Musculocutaneous Flaps*. St. Louis: Mosby, 1982. Pp. 364-385.

- TFL flap has advantage of being an expandable flap with a large arc of rotation that can reach upper abdominal wall.
 - Flap of choice for middle and lower abdominal wall
 - Drawback: limited by donor morbidity because harvesting > 8 cm requires skin graft for closure
- Rectus femoris: used for repair of lower 2/3 of abdomen.
 - A strong muscle with a large arc of rotation recommended in chronically infected wounds
 - Drawback: donor morbidity; especially weakening of quadriceps function
- The gracilis and vastus lateralis are second-choice muscle flaps for the anterior abdominal wall

Free Flap

- Considered when local tissues have been previously destroyed or when a pedicled flap cannot reach or is insufficient in size to cover a defect
- Must have a suitable recipient vessel
 - most commonly used are inferior epigastric, deep circumflex iliac, superior epigastric, internal thoracic
- The tensor fascia lata is the most common free flap used for abdominal wall reconstruction.
- Latissimus dorsi flap also utilized as a free flap for abdominal wall reconstruction

Joshua A. Lampert, MD
September 29, 2005