

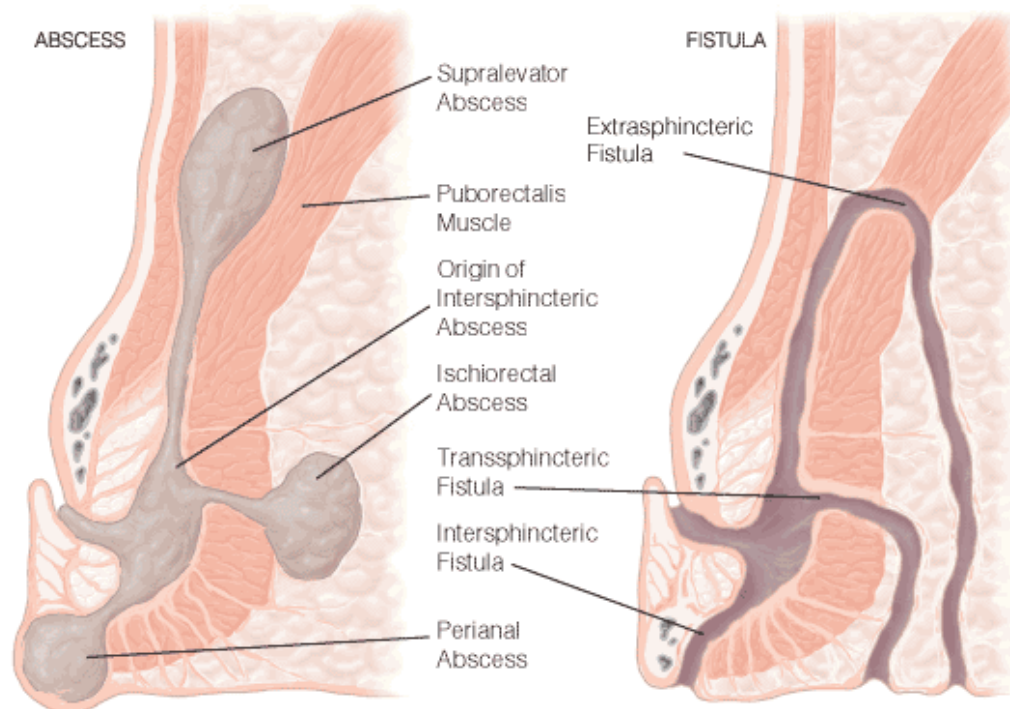
ANAL ABSCESS AND FISTULA

INTRODUCTION

- in general population 20 % have anorectal discomfort (the ages 21-65).

ABSCESS

- It is an infection in one or more of the anal spaces.
- Infected blocked anal glands.
- Severe pain, constant, fever, malaise, purulent anal discharge.
- Fluctuation, a patch of erythematous, indurated skin or no findings.



Horseshoe/deep post-anal space abscess: posterior to the anal canal.

Differential diagnosis.

- infected presacral epidermal inclusion cyst
- hidradenitis suppurativa
- pilonidal disease
- Bartholin's abscess

Treatment

- Anal abscess :
- Incision and drainage
- adequate incision or excision of overlying skin

- inserting a drainage catheter
- or placement of a seton
- Antibiotics only in special circumstances:
 - valvular heart diseases
 - immunosuppression
 - extensive cellulites
 - diabetes

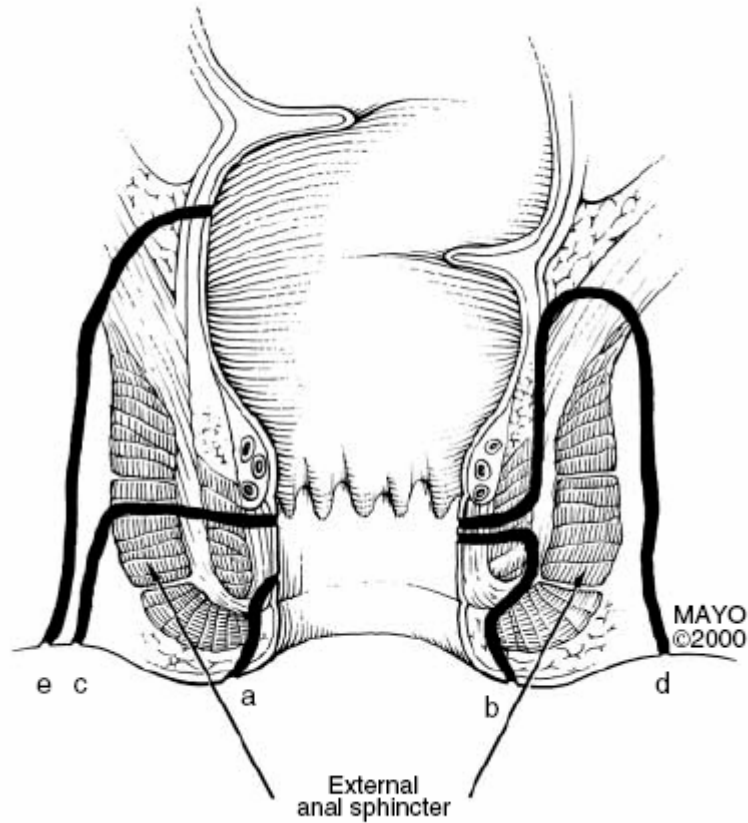
FISTULA-IN-ANO

- Incidence 8.6 per 100.000
- Nonspecific - 90%
- Postoperative or traumatic - 3%
- Fistulas arising from an anal fissure – 3%
- Fistulas arising from inflammatory bowel disease - 3%
- Tuberculosis - 1%
- Anorectal malignancy
- Actinomycosis
- Lymphogranuloma venereum

- Average age 38, men to women of 1.8 to 1
- in 35-50% anorectal abscess develop into fistula

- **Clinical Manifestation and Diagnosis**
 - “Non-healing” anorectal abscess.
 - Pustule-like lesion.
 - Pain during defecation.
 - Perianal excoriation and itchy.
 - Associated symptoms (according to main disease).

- **Imaging Tests**
 - Fistulography
 - CT
 - MRI- accurate
 - Endosonography- accurate

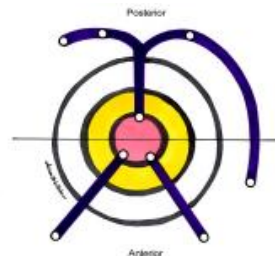


Source: Aliment Pharmacol Ther © 2004 Blackwell Publishing

- A -superficial
- B -inter- sphincteric
- C -trans-sphincteric
- D -supra-sphincteric
- E -extra-sphincteric

Treatment

The goal- to eradicate the fistula while preserving fecal continence.

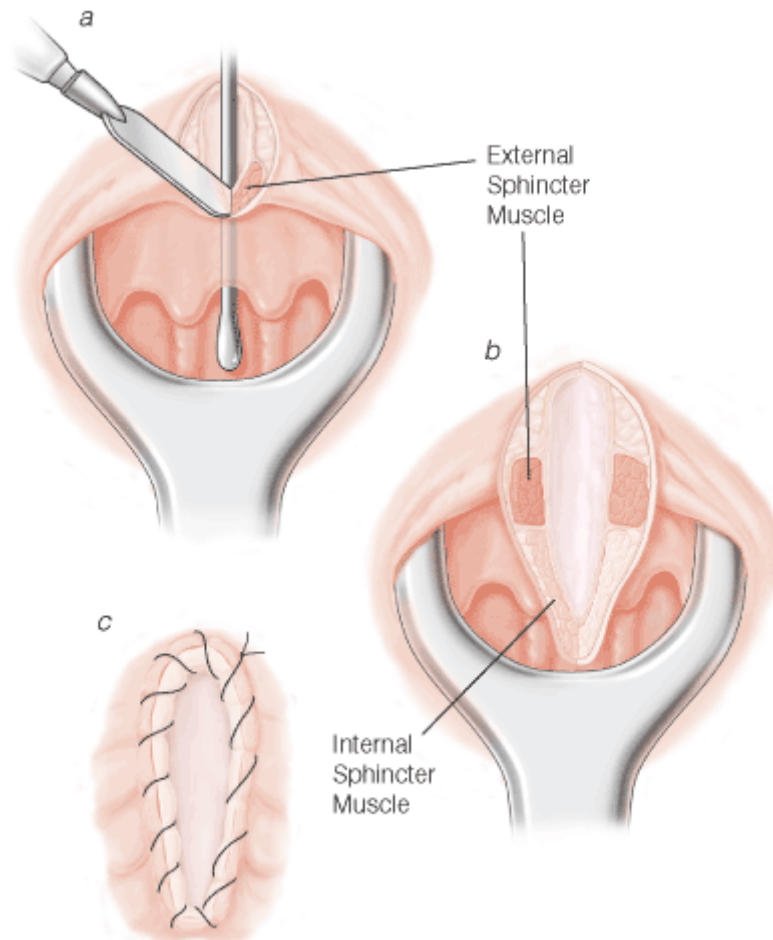


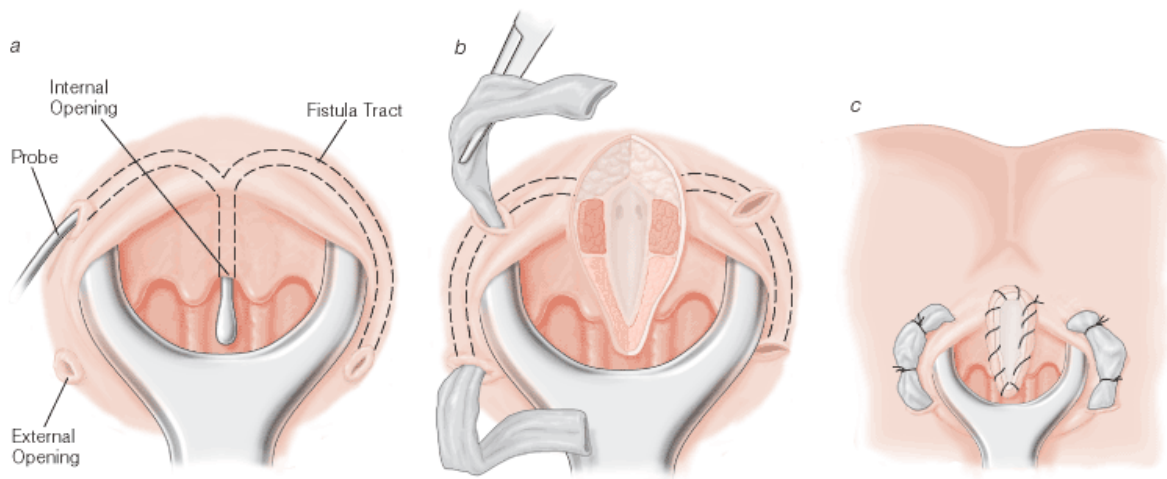
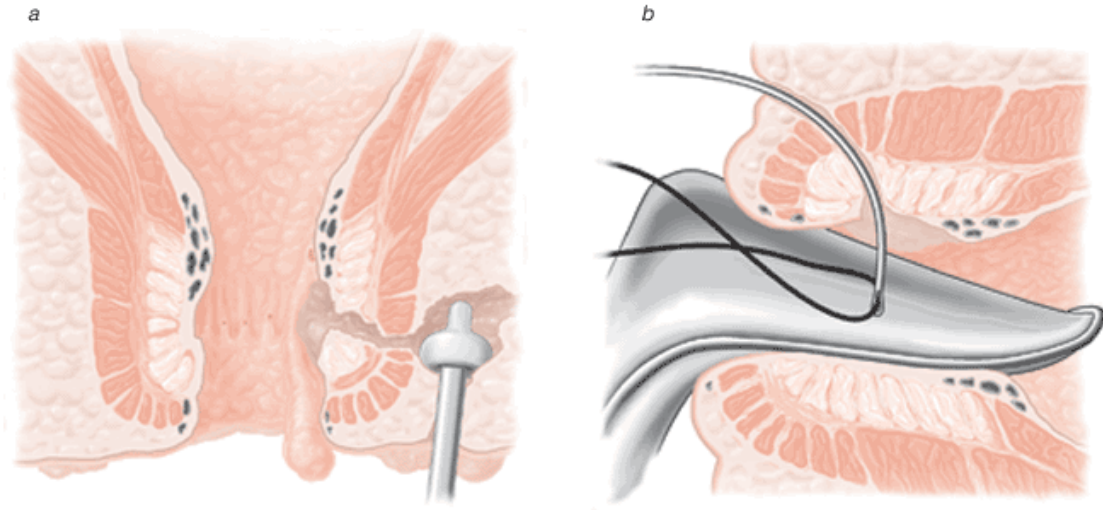
GOODSALL'S RULE

All fistula tracts with external openings within 3 cm of the anal verge and posterior to a line drawn through the ischial spines travel in a curvilinear fashion to the posterior line midline. All tracts with external openings anterior to this line enter the anal canal in a radial fashion.

The American Society of Colon and Rectal Surgeons

- Simple anal fistula
 - fistulotomy
 - track debridement and fibrin glue injection
- Complex anal fistula
 - debridement and fibrin glue injection
 - endorectal advancement flap closure
 - use of seton and / or staged fistulotomy
- Crohn's disease
 - asymptomatic Crohn's disease need not be treated
 - simple, low Crohn's fistula may be treated by fistulotomy
 - complex Crohn's fistula may be well palliated with long-term draining setons.
 - complex Crohn's fistula may be treated with advancement flap closure if the rectal mucosa is grossly normal





Nikolay Bugaev, M.D.
November 7, 2005