

COLONIC PSEUDO-OBSTRUCTION OGILVIE'S SYNDROME

- Intestinal pseudo-obstruction, a profound ileus without evidence of mechanical obstruction, was first described by Ingelfinger in 1943.
- The first description of the colonic variant of pseudo-obstruction is thought to be Sir Heneage Ogilvie's 1948 report of two cases associated with malignant infiltration of the celiac plexus.
- Colonic pseudo-obstruction is associated with neuroleptic medications, opiates, malignancy, severe metabolic illness, or any acute severe illness. Excess sympathetic tone has been postulated as the common mechanism.
- This concept is supported by anecdotal reports of success with epidural anesthesia, which paralyzes the sympathetic afferent and efferent nerve fibers to the colon and with neostigmine, which increases parasympathetic tone by its anticholinesterase effect.
- The diagnosis of colonic pseudo-obstruction is one of exclusion; a water-soluble contrast enema or colonoscopy should be performed to exclude mechanical obstruction.
- Initial treatment maneuvers include nasogastric decompression, rectal tube placement, correction of metabolic disorders, and discontinuation of medications that decrease colonic motility (e.g., narcotics and anticholinergics).
- Evidence of rapid cecal dilatation or a cecal diameter greater than 11 to 12 cm on abdominal x-ray should prompt more aggressive intervention because of the risk of cecal ischemia, necrosis and perforation.
- Colonoscopic decompression is successful initially in 70 to 90 percent of patients, with a recurrence rate of 10 to 30 percent.
- The majority of patients will respond to a second colonoscopic decompression. The use of long colonic tubes has not been uniformly successful.
- Operation is reserved for patients with persistent colonic dilatation despite colonoscopic decompression and patients with peritonitis. Cecostomy or loop colostomy is effective in relieving distention; laparotomy should be performed in patients with peritonitis, and nonviable bowel should be resected.

Ponec RJ, Saunders MD, Kimmey MB.

Neostigmine for the treatment of acute colonic pseudo-obstruction.
N Engl J Med. 1999 Jul 15;341(3):137-41.

Paran H, Silverberg D, Mayo A, Schwartz I, Neufeld D, Freund U.

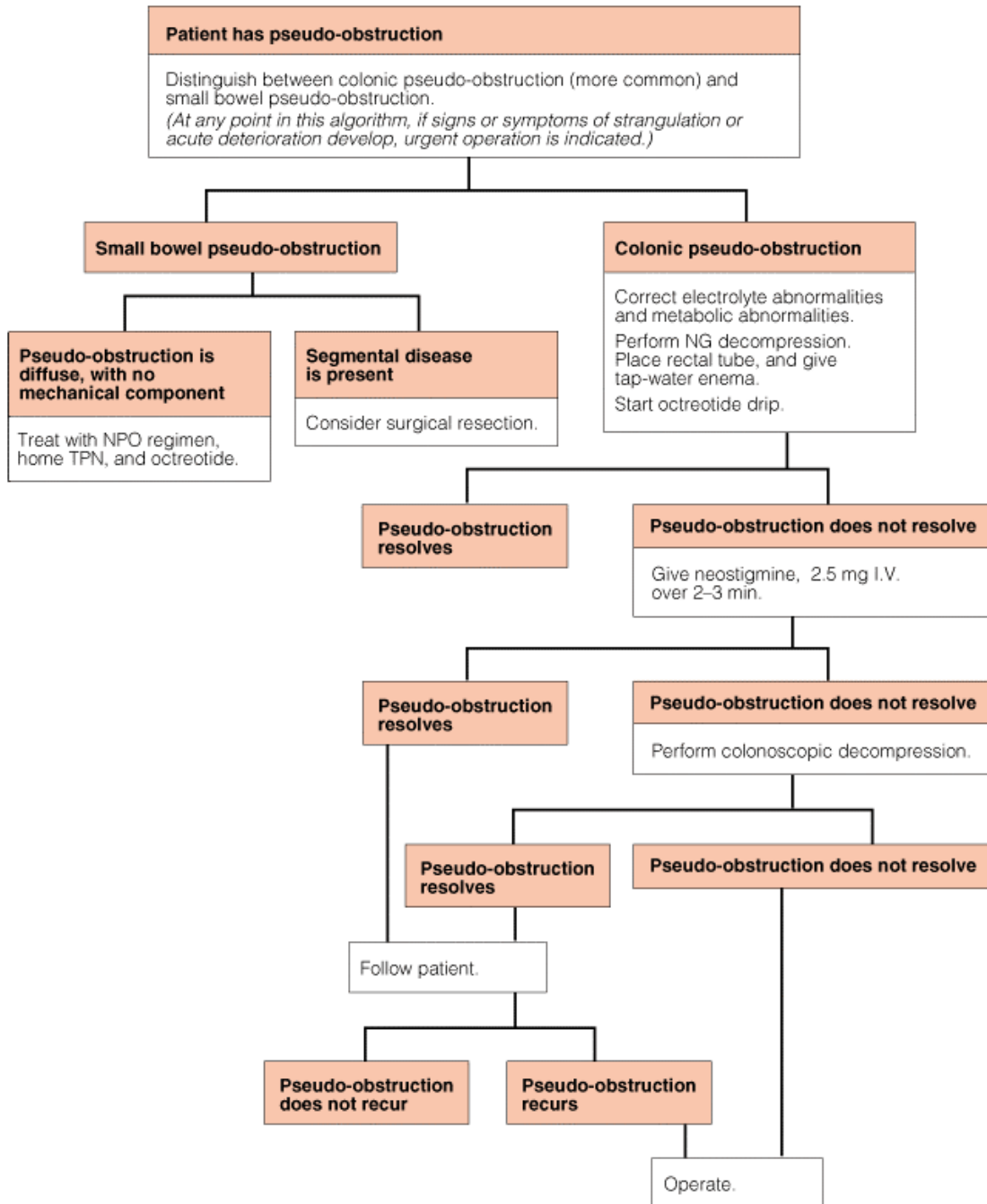
Treatment of acute colonic pseudo-obstruction with neostigmine.
J Am Coll Surg. 2000 Mar;190(3):315-8.

Vanek VW, Al-Salti M.

Acute pseudo-obstruction of the colon (Ogilvie's syndrome). An analysis of 400 cases.
Dis Colon Rectum. 1986 Mar;29(3):203-10.

Principles of surgery/editors, Seymour I. Schwartz . . . [et al.]. —
7th ed., New York: McGraw-Hill, 2000

ACS surgery: principles & practice / [editors] Douglas W. Wilmore ... [et al.]



Sergey Khaitov, M.D.