

RECTAL PERFORATION

Causes:

- Trauma:
 - Gunshot wound
 - Stab wound
 - Blunt trauma
 - Impalement
- Iatrogenic:
 - Colonoscopy
 - Barium enema
 - Cleansing Enemas
 - Pelvic surgery
 - Stapling device – hemorrhoids
- Retained surgical drain
- Anal intercourse
- Foreign bodies

Evaluation:

- History (penetrating trauma of lower abdomen, pelvis, pelvic fracture)
- Exam:
 - Blood on digital exam
 - hematoma
 - contusion
 - laceration
 - gross blood PR

Imaging:

- Proctoscopy/sigmoidoscopy
- Plain films
- CT

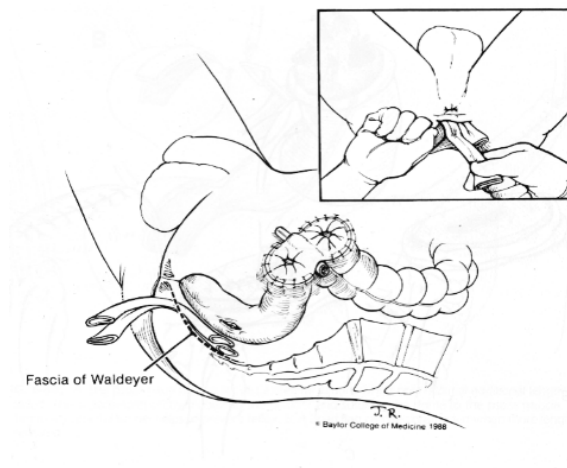
Treatment:

1. Closure of injury
 2. Diversion
 3. Rectal washout
 4. Presacral drainage
 5. Antibiotics.
- Intraperitoneal: debridement/ primary repair.
 - Large wounds, associated injuries: resection/ colostomy (Hartmann)
 - Extraperitoneal: Not necessary to identify injury or close wound.
 - loop colostomy,
 - drainage (penrose, closed suction) through retroanal incision
 - Irrigation of rectum- debatable

Iatrogenic injuries:

- Endoscopic: Bowel prep=> reduced fecal contamination- primary repair
- Barium enema: significant mortality (50%)=> diversion

- Conservative management
 - Chu, Am Surg 1999- extraperitoneal perforation from colonoscopy.
 - Criteria:
 - below reflection
 - bowel prep
 - no signs of infection
 - Madhala, Dig surg.1998 2 patientsts s/p barium and cleansing enema- non surgical treatment.



References:

1. Handbook of Trauma, *Wilson, Rectal injuries, 1999*
2. Fundamentals of Colorectal Surgery, *Beck & Wexner, 1998*
3. *Cameron: Current Surgical Therapy 2001*
4. Enema induced perforation of the rectum, *Paran: DCR, Dec. 1999*
5. Rectal perforation after stapling procedure for prolapsed hemorrhoids, *Ripetti, DCR, Feb. 2002*
6. Extraperitoneal rectal perforation caused by retroflexion proctoscopy, *Chu, Am Surg Jan 1999*
7. Rectal perforation caused by enema: is surgery mandatory? *Madhalla, Dig Surg, Jan 1998*